

RADIOGRAPHIC EVALUATION OF SOFT PALATE MORPHOLOGY AND CORRELATION WITH GENDER ON LATERAL CEPHALOGRAMS

KESAV READDY

INTRODUCTION

The delicate sense of taste is the back fibro solid piece of the sense of taste that is appended to the back edge of the hard sense of taste. It partakes in a large portion of the oral capacities, particularly in velopharyngeal conclusion which is identified with the typical elements of sucking, gulping and articulation. The sense of taste is shaped by the combination of three segments; the two palatal procedures and the frontonasal procedure. At a later stage, the mesoderm in the sense of taste experiences intramembraneous hardening to frame the hard sense of taste. In any case, the hardening does not stretch out into the most back bit which stays as the delicate sense of taste. Early references concerning the target estimations of the delicate sense of taste have been finished by agents for appraisal of discourse, work and the upper aviation route structures. In spite of the fact that these proceeded with endeavors toward the dimensional examination of the delicate sense of taste and its encompassing structures have been made, little consideration has been paid to the assortment of delicate sense of taste morphology and design. Picture of the delicate sense of taste on sidelong cephalometry seems to have different morphologies in typical people, rather than the just a single kind distributed in the writing. Pepin et al found the "snared" appearance of the delicate sense of taste in patients who were conscious, which demonstrated a high hazard for the obstructive rest apnoea disorder.

The reason for the present examination is to explore the variety of the delicate sense of taste morphology and the corresponding contrasts of the delicate sense of taste between the two sex gatherings. This investigation can be useful for understanding the different morphologies of the delicate sense of taste in the middle sagittal plane on parallel cephalograms. These discoveries might be utilized not just as references for the ordinary delicate sense of taste, yet in addition for parted recreation and the etiological research of obstructive rest apnea disorder (OSAS) and different conditions.

MATERIALS AND METHODS

We led a cross-sectional investigation in branch of Oral Medicine and Radiology, Manipal College of Dental Sciences, Manipal. Instructional moral advisory group endorsement was gotten for the examination. Parallel cephalometric radiographs of people subjected to radiographic examination for orthodontic reason for existing were recovered for the investigation from the chronicles of bureaus of Oral Medicine and Radiology and Orthodontics. A sum of 100 advanced sidelong cephalograms of ordinary solid people (50 guys and 50 females) who were matured 15-45 years were recovered from November 2014 to February 2015. Every one of the subjects who had ordinary discourse and capacity were incorporated into this investigation. Radiographs of good quality and perceivability of

delicate sense of taste were incorporated. Patients with facial or palatal disfigurements or facial injury were barred. Low quality radiographs and radiographs with fragmented points of interest were additionally rejected.

All horizontal cephalograms were taken utilizing orthopantomograph (Planmeca) with a tube potential acclimated to advance the difference. Every one of the pictures on the radiographs were watched and grouped into 6 writes by 2 radiologists autonomously as indicated by You M et al., (2008). The six kinds of morphology of the delicate sense of taste are as per the following:

1. Type 1: "leaf shape", which was lanceolate, shown that the center part of the delicate sense of taste hoisted to both the naso and the oro-side
2. Type 2: when the delicate sense of taste demonstrated that the foremost bit was swelled and the free edge had a conspicuous coarctation, the radiographic appearance was portrayed as having a "rodent tail shape"
3. Type 3: a "butt-like" delicate sense of taste demonstrated a shorter and fatter velum appearance, and the width had no particular distinction from the foremost segment to the free edge
4. Type 4 showed that the picture of the delicate sense of taste introduced a "straight line shape"
5. Type 5: the mutilated delicate sense of taste, introduced the S-shape
6. Type 6 uncovered a "hooligan" appearance of the delicate sense of taste, in which the back part of the delicate sense of taste convicts anterosuperiorly

The example of the delicate sense of taste on the advanced horizontal cephalograms was featured with bend instrument in Microsoft control point. The evaluation of the delicate sense of taste morphology was completed twice by two radiologists. Since there were no distinctions in characterization between the two radiologists, unwavering quality was thought to be worthy.

All the examination was finished utilizing SPSS form 18. A p-estimation of <0.05 was considered factually critical. Correlation of variety of delicate sense of taste morphology amongst guys and females was finished utilizing Chi-square test.

RESULTS

An aggregate 100 radiographs were considered for states of delicate sense of taste out of which 50 were guys. The age of the subjects was 20.91 ± 3.63 with age scope of 18 – 45 years. Sort 1 was most commonest state of the delicate sense of taste (30%) trailed by Type 6 (19%), Type 2 and 3 (17% and 17%), type 4 (11%) with slightest being type 5 (6%) (Figure 1).

An aggregate of 50 male and 50 female radiographs were utilized for our examination. Among guys, Type 1 was the commonest (38%) trailed by type 6 (22%), Type 2 and 3 (14 and 14) with minimum being type 4 and 5 (6 and 6%) individually. In females, Type 1 (22%) was the commonest taken after by type 2 and 3 (20 and 20%), type 4 (16%), type 6 (16%) with slightest being type 5 (6%). Be that as it may, there was no noteworthy distinction in the circulation of state of delicate sense of taste amongst guys and females ($p=0.312$) (Table 1).

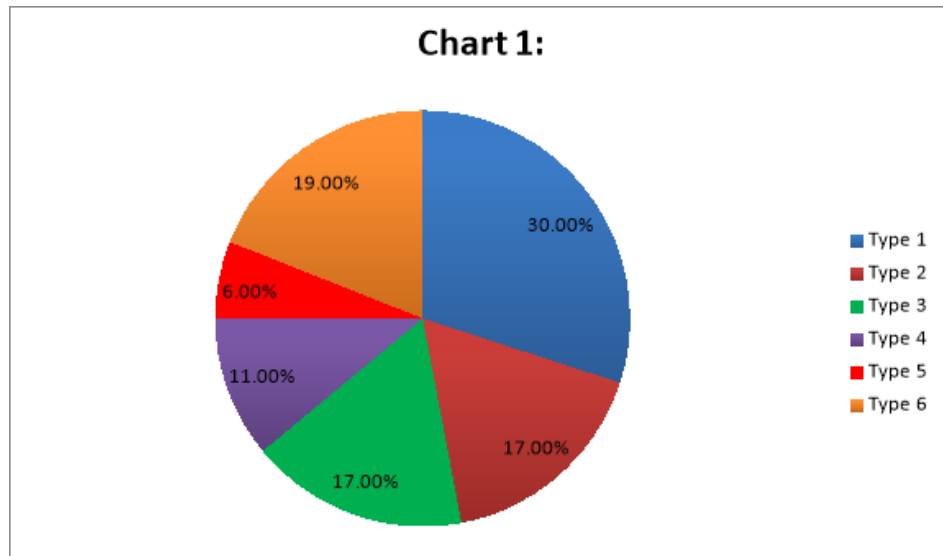


Table 1: Comparison of shape of soft palate between males and females

Type	Gender	N	%	p-value
1	Male	19	38.0%	0.312; NS
	Female	12	22.0%	
2	Male	7	14.0%	0.20
	Female	7	14.0%	
3	Male	7	14.0%	0.20
	Female	7	14.0%	
4	Male	3	6.0%	0.16
	Female	8	16.0%	
5	Male	3	6.0%	0.06
	Female	3	6.0%	
6	Male	11	22.0%	0.16
	Female	8	16.0%	

Chi-square test

DISCUSSION

Cephalometric examination is a standout amongst the most ordinarily acknowledged strategies for assessing the delicate sense of taste in both typical people and those with congenital fissure. Cephalometry is a moderately cheap strategy and grants a decent evaluation of the delicate tissue components that characterize the delicate sense of taste morphology and its encompassing structures.

A significant part of the previous research that concentrated the delicate sense of taste and its encompassing structures was gone for giving some data on determination, expectation and treatment in people with congenital fissure. The delicate sense of taste assumes an expansive part in velopharyngeal conclusion, which alludes to the ordinary pairing of the delicate sense of taste with the back and horizontal pharyngeal dividers. It is essentially a

sphincteric instrument comprising of velar and pharyngeal parts. The development isolates the oral hole from the nasal cavity amid deglutition and discourse. At the point when the velum and horizontal and back pharyngeal dividers neglect to isolate the two cavities, velopharyngeal inadequacy (VPI) happens.

In our examination, the leaf-molded delicate sense of taste was the most continuous write, which is a normal finding since this compose was beforehand depicted as an exemplary velar morphology in the writing. This was as per the past examinations revealed in the writing. Be that as it may, Type - 2 (Rat tail formed) was accounted for to be commonest by Praveen et al., 2011. While the S-shape was seen in just couple of cases, it can be gathered that the quantity of subjects in the examination was not sufficiently substantial. The S-shape, which was portrayed as a snared appearance of the delicate sense of taste by Pepin et al., was found in 5.8% subjects in our investigation. They guessed that delicate sense of taste snaring assumes a key part in pharyngeal fall, since snaring brings about a sudden and significant lessening in the oropharyngeal measurements, which subsequently drastically builds upper aviation route protection and the transpharyngeal weight inclination. Pepin et al., in this manner reasoned that snaring of the delicate sense of taste in alert patients shows a high hazard for OSAS.

In our investigation, the distinction between sexual orientation didn't exist in the examination of the extent of the different morphology of delicate sense of taste. This was like that revealed by Praveen et al., 2011 while past examination by You et al. revealed sex contrasts, wherein type 2 and 3 were fundamentally less in females than guys. Sort 1 was the most remarks write among guys and females in our investigation which was trailed by type 2 and 3. This was like the investigation detailed by Kruthika S et al., 2012.

This characterization can enable us to better comprehend the assorted variety of the velar morphology in the middle sagittal plane. These discoveries can be utilized as references for the examination of velopharyngeal conclusion in congenital fissure people and for a etiological research of OSAS and different conditions.

REFERENCES

1. Johns DF, Rohrich RJ, Awada M. Velopharyngeal incompetence: a guide for clinical evaluation. *Plas Reconstr Surg* 2003
2. Subtelny JD. A cephalometric study of the growth of the soft palate. *Plast Reconstr Surg* Pp.49-62.
3. Satoh K, Wada T, Tachimura T, Fukuda J, Shiba R, Sakoda S, et al. Comparison of the nasopharyngeal growth between patients with clefts (UCLP) and those with non-cleft controls by multivariate analysis. *Cleft Palate Craniofac J* 1997.
4. Johnston CD, Richardson A. Cephalometric changes in the adult pharyngeal morphology. *Eur J Orthod* 1999
5. Taylor M, Hans MG, Strohl KP, Nelson S, Broadbent BH. Soft tissue growth of the oropharynx. *Angle Orthodont* 1996
6. Kollias I, Krogstad O. Adult craniocervical and pharyngeal changes—a longitudinal cephalometric study between 22 and 42 years of age. Part II: morphology of the uvulo glossopharyngeal changes. *Eur J Orthod* 1999
7. Maltais F, Carrier G Cormier Y, Series F. Cephalometric measurements in snorers, non-snorers, and patients with sleep apnoea. *Thorax* 1991.