



A Peer Reviewed Refereed Journal

## AN AUTOMATIC HUMAN IDENTIFICATION USING DENTAL PANORAMIC X-RAY IMAGES

MERLY DANIEL<sup>1</sup>, JYOTHI UNNITHAN<sup>2</sup>, MERRISH DANIEL<sup>3</sup>  
& PROF.SAGAR JOSHI<sup>4</sup>

<sup>(1234)</sup> *Department of E&TC, Nutan Maharashtra Institute of Engineering and Technology, Talegaon, Pune, India*

### ABSTRACT

*The most popular biometrics used in the process of forensic human identification is Dental Radiographic Images. This led to the creation of the Automatic Dental Identification System which takes lesser time to perform a single search in a large database of dental records. A prior segmentation of the radiogram into sections containing a single tooth will be need for the fully automated system identifying people based on dental X-ray images. In this paper, a new method of segmentation is presented, developed for the dental radiographic Images depicting pan tomograms. It does not depend on the articulation of gaps between adjacent teeth, but the described method utilizes the locations of areas between necks of teeth to determine the separating line which improves the results achieved in the situation of severe occlusions.*

**KEY-WORDS:** *image segmentation, dental pan tomography, dental human identification, ADIS, forensic identification.*

## 1. INTRODUCTION

The one of the main applications of pattern recognition is the Automatic human identification. Various biometrics have been used as a basis for such identification, e.g. handwriting, iris, face, fingerprints etc. In reality, there exist situations where some of that biometrics cannot be applied. Post-mortem (PM) identification, performed by experts in forensic medicine, consists in determining the identity of a deceased person. This undermines the ability to use some biometrics, such as handwriting or voice, but in some instances there might be other factors rendering other biometrics useless or impractical, for example face recognition in case of fire victims or DNA matching in case of mass natural disasters with multiple casualties. Dental characteristics are popularly used in forensics because of both their robustness to decomposition as well as the speed of a single identification ([1]).

The goal of the system is to provide the ability to narrow the search for an individual in the DIR by automatically finding a small number of the most similar X-ray images. This speeds up the process of a single identification, as out of a large database of images only a small number of comparisons needs to be performed by a forensic expert. The model and functionality of ADIS were presented in [2]. ADIS focuses on teeth morphology

uses teeth contours extracted from dental radiograms in the process of matching.

The simplified model of ADIS assumes three preliminary steps before the comparison: image enhancement, image segmentation and feature extraction ([5]). The first step focuses on improving the contrast of the image, which is usually of low quality. The second step, image segmentation, separates the image into disjunctive segments, each containing at most one tooth. The last step, feature extraction, detects the shape of the contour of a tooth, if present on a given segment, and saves the result in a form that will later be used in the comparison process. While there exist numerous approaches to each of the preliminary steps for intraoral images (i.e. photographs taken with the x-ray film situated inside the patient's mouth, thus showing only a fragment of his dentition), few approaches have been developed for panoramic extra oral images (i.e. photographs taken with both X-ray tube and film moving on an arc on the opposite sides of the patient's head, thus showing the full dentition). Panoramic images, or pan tomograms, convey the largest amount of information of all types of dental radiographic images because they show the widest range of dentition.

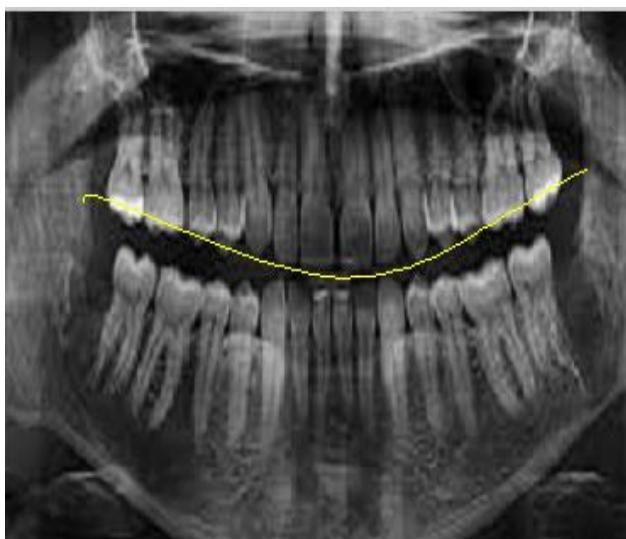## 2. PRESENTED METHODS:

### 2.1 Initial steps:

From our learning, it's clear that there no clear method existing for segmentation of pan tomograms so this has led to development of new techniques. Few processing are done before an image undergoes segmentation, it is enhanced by separating the image into a Laplacian pyramid, and it undergoes dividing the radiograms into smaller images having lower frequency to the signals in original image. Later filters are applied to the chosen layers of pyramid, which involve use of sharpening and contrast enhancement methods, no later than image is recomposed back. The image obtained after processing has a higher contrast than the original with slight increase in noise. Gap between the frontal teeth should locate before doing segmentation. A vertical line is drawn through the noise position and that point is selected as the center.

### 2.2 Separation of upper & lower jaw:

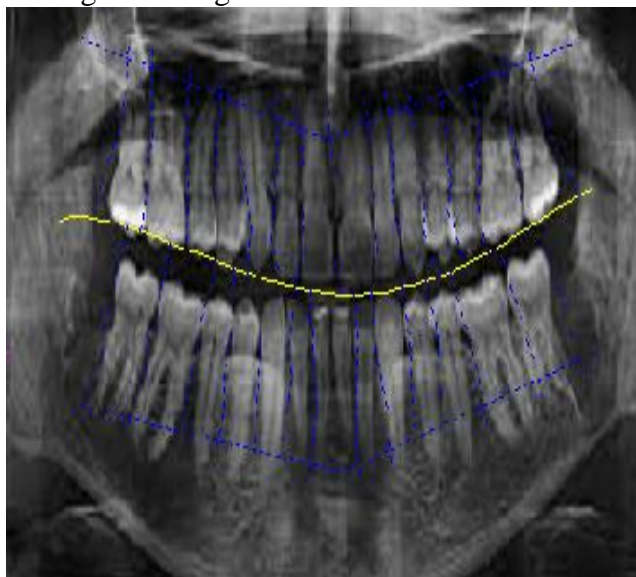
First step is to determine the line that separates upper and lower jaw which is shown in fig 1. To carryout automatic segmentation process a horizontal integral projection is chosen that has the lowest value which is closer to the center of image approx between 40%-60% of its height. Only a small number of pixels closer to the earlier chosen frontal teeth gap are used to calculate projection instead of the full horizontal line that would pass through teeth further through the incisors.



**Fig 1:** Splines passing through the dental pulp that indicates height on which the necks of teeth can be found and the spline that separates upper and lower jaw (middle line).

### 2.3 Separation of individual teeth

To know the angle of the segmenting line molars and, in some cases, premolars need an additional step of algorithm. An additional step required to be found between them, In order to find a straight line separating these teeth. A simple algorithm known as greedy algorithm was used, repetitively moving 1 pixel towards the top or bottoms of the picture, selecting the pixel in horizontal proximity with the highest intensity on the inverted and range filtered image and use it as the starting point for the next repetition. The position of the last result becomes the second separating point and the line passing through the gap between necks of teeth and second separating points becomes the segmentation line when the number of repetition equal to the half of the length of an average tooth on a pantamogram. The roots of the tooth need to be distinguish sufficient from the background and neighboring teeth is one of the drawbacks of this approach of finding the second separating point, so using that algorithm with incisors and canines most of the time produces faulty results. Using this algorithm the separating lines are obtained on a simple pantomogram on fig 2.



**Fig 2:** Separation of individual teeth using line on the pantomogram. Vertical lines are for incisors and canines, while rotated lines are used for molars which are achieved by determining two points between the teeth.

### 2.4 Feature Extraction:

Feature extraction process follows tooth segmentation wherein some specific features are defined which are further used for matching post-mortem (PM) images with ante mortem (AM) images. There are many features available in literature for comparing AM and PM dental radiograph images. The features are used solely for comparing the radiographs i.e. identification purposes. In this paper we extract many geometrical features of individual tooth namely: teeth area (%), major axis length, minor axis length & fourier descriptors.

## EXPERIMENTS:

The introduced dental X-ray-based identification method has been applied to some query images for accessing data from a database, which contains many AM images. In each query image, we portioned the teeth into two sections: the teeth in the upper jaw and the teeth in the lower jaw. The teeth in the same group will not change their relative positions, while teeth from different groups will probably change their relative positions because of the opening and closing of the mouth during image capture. Therefore, we separately match the two groups of teeth. It shows some examples of query images matched with a real and an impostor image in the database. As compared to the impostor teeth, matching distance between the query image and the genuine teeth is smaller. We evaluated the query images that were not perfectly matched and identified the following reasons for these mismatches: (i) inadequate quality of images, resulting in errors in tooth extraction,(ii) Some tooth were only partially visible and (iii) the natural

similarity between teeth shapes of different individuals.

## CONCLUSIONS AND FUTURE WORK:

A new automatic method of human identification based on dental radiographs is introduced. This method involves three stages: radiograph segmentation, tooth feature extraction, and tooth feature matching. The feature utilized here is the contours of the teeth. A probabilistic model is used to describe the classification of tooth pixels and background pixels in the image. After the tooth contours are drawn out, a transformation is used to form a line the contours to correct the imaging geometric variations and a matching distance is procreate. The final decision is obtained with respect to the matching distances. Introductory experiments on a small database indicate that it is a achievable approach. Future work will involve utilizing these additional sources of information to improve the reliability of person identification with dental images. Meanwhile, since several PM images are usually available for a single person and each PM image generates a list of retrievals, we are currently working on combining these results to provide a better retrieval. In addition, we are developing an image restoration algorithm to handle poor quality radiographs. We also plan to evaluate our algorithm on a larger database of dental radiographs.

## REFERENCES

- [1] S. Lee et al. The diversity of dental patterns in orthopantomography and its significance in human identification. *J Forensic Science*, 49(4), 2004.
- [2] D.E.M. Nassar, H.H. Ammar. A prototype automated dental identification system (ADIS). In *Proceedings of the 2003 annual national conference on Digital government research*, 2003.
- [3] M. Abdel-Mottaleb et al. Challenges of developing an automated dental identification system. In *IEEE Mid-west Symposium for Circuits and Systems*, Cairo, Egypt, 2003.
- [4] C. Michael Bowers. *Forensic Dental Evidence*. Elsevier, 2004.
- [5] A.K. Jain et al. Toward an automated dental identification system(ADIS). In *Proc. Int. Conf. Biometric Authentication*, Hong Kong, China, 2004.
- [6] A.K. Jain, H. Chen. Matching of dental x-ray images for human identification. *Pattern Recognition*, 37(7), 2004.
- [7] A. Said et al. Dental x-ray image segmentation. In *SPIE Technologies for Homeland Security and Law Enforcement conference*, 2001.
- [8] J. Zhou, M. Abdel-Mottaleb. A content-based system for human identification based on bitewing dental xray images. *Pattern Recognition*, 38(11), 2005.
- [9] M. Kass, A. Witkin, D. Terzopoulos. Snakes: Active contour models. *International Journal of Computer Vision*, 1(4), 1988.
- [10] D. Frejlichowski, R. Wanat. Application of the Laplacian pyramid decomposition to the enhancement of digital dental radiographic images for the automatic person identification. In *Image Analysis and Recognition 7th International Conference*, 2010.